



MARCH
21ST & 22ND
2019
PADUA
ITALY

CLIC
Critical Limb Ischemia Course

LIVE CASES
Thursday, March 21st

CASE 1

Operators:

Dr. Palena – Dr. Herrero – Dr. Thomas

UNRESTRICTED
SPONSORING

COOK[®]

MEDICAL

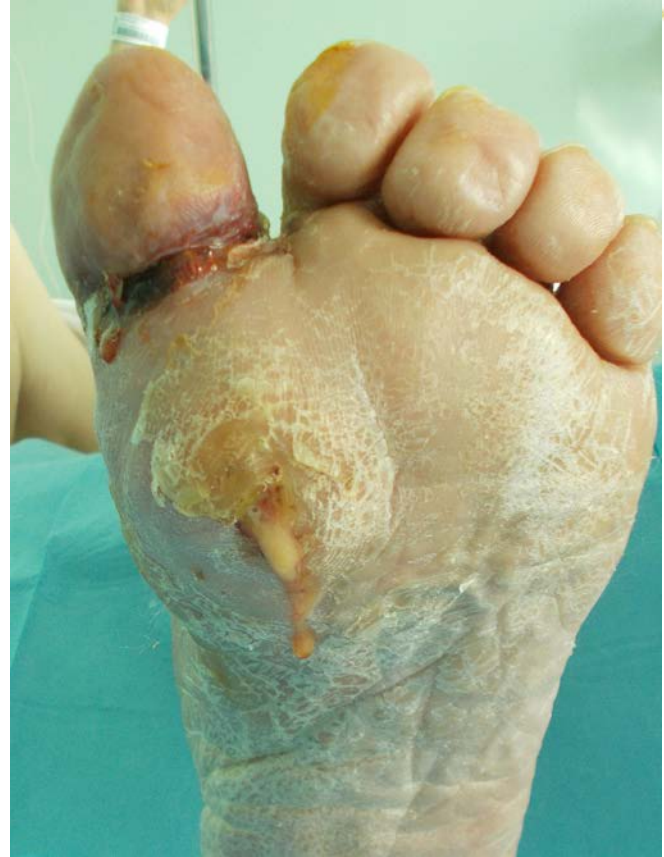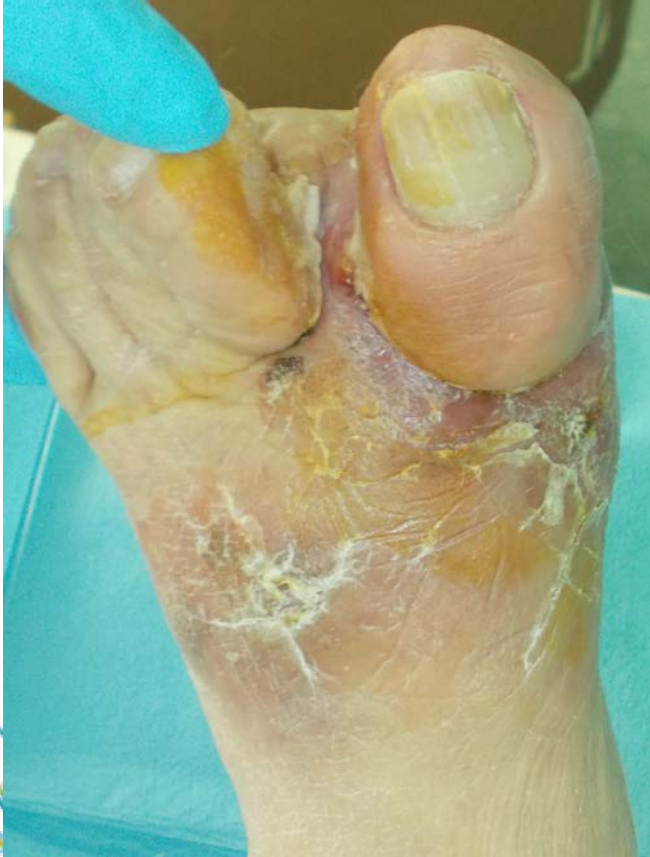CASE 1

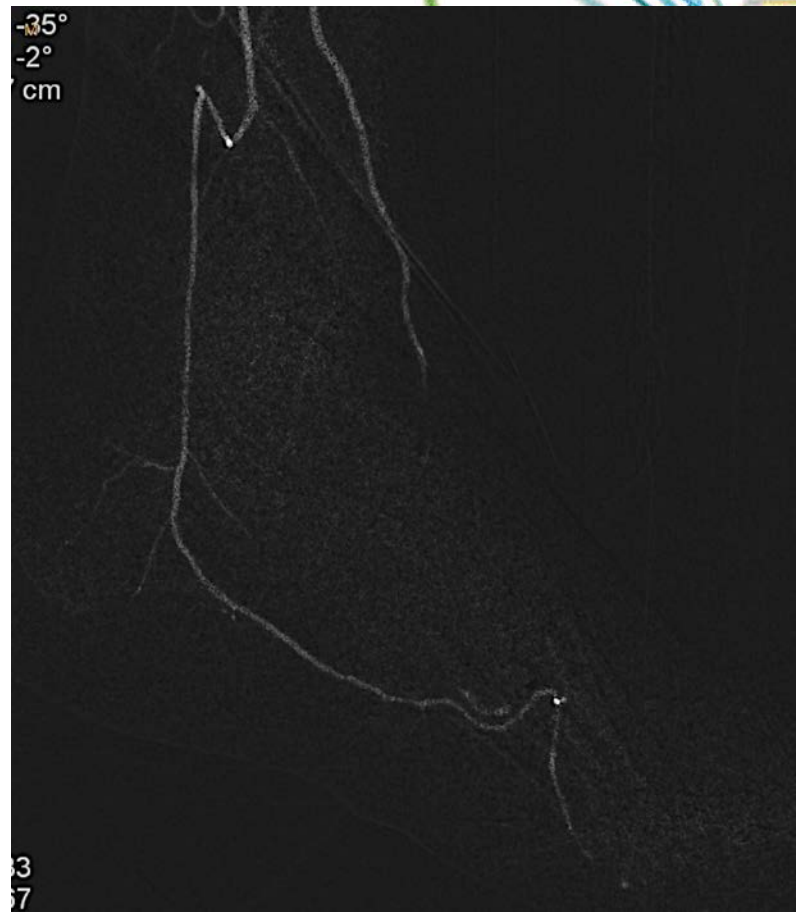
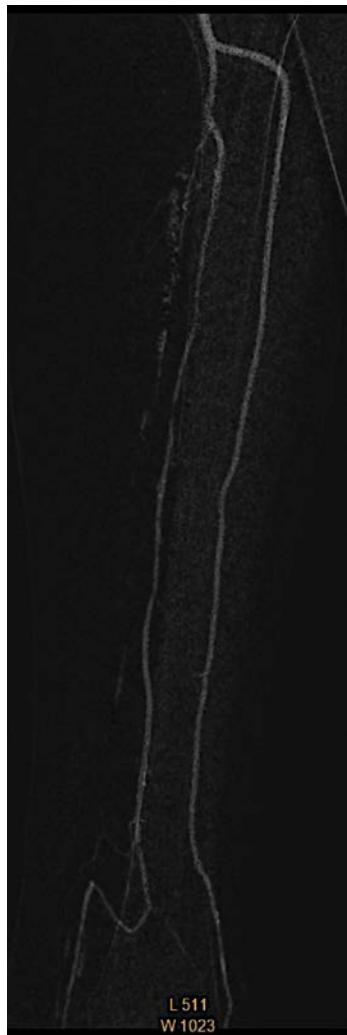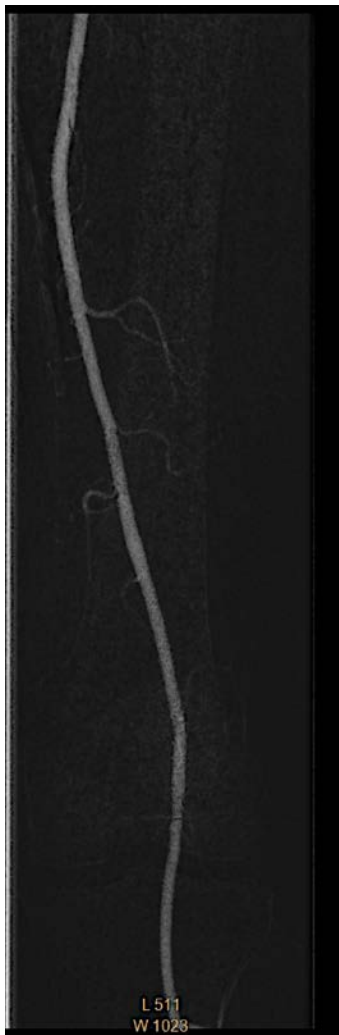
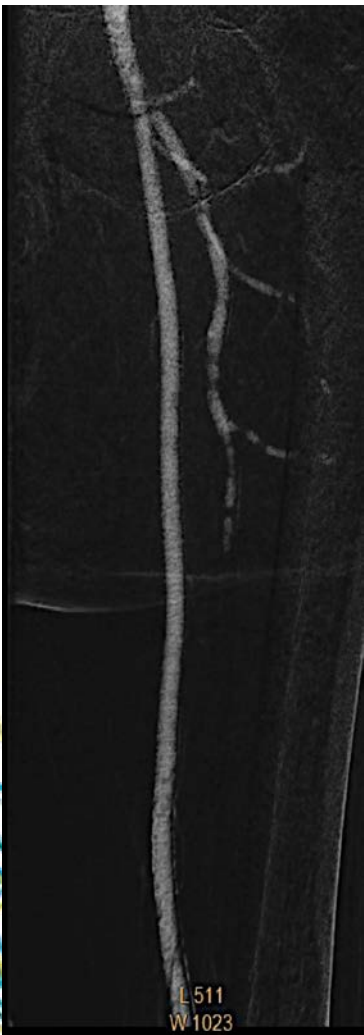Male, 78 y-o, type 2 diabetes since 15 years, dyslipidemia. CRF (1,5 creatinine)

Left CLI. Phlegmon of the forefoot (4-5 mpj), surgically drained. Previous antegrade attempt in PT, failed, in a plantar dominance situation.

CO2 Angio of the Left limb.

CASE 1





CASE 1

Strategy:

Antegrade 6F access. Retrograde access in distal PT (Pedal access set). CXI micro-catheter.

Hydro-ST 0.014 Guide wire.

Micro balloon – Advance LP 0.014 PTA