



MARCH  
21<sup>ST</sup> & 22<sup>ND</sup>  
2019  
PADUA  
ITALY

**CLIC**  
Critical Limb Ischemia Course

**LIVE CASES**  
**Thursday, March 21<sup>st</sup>**

# CASE 3

## Operators:

Dr. Palena – Dr. Herrero – Dr. Thomas

UNRESTRICTED  
SPONSORING



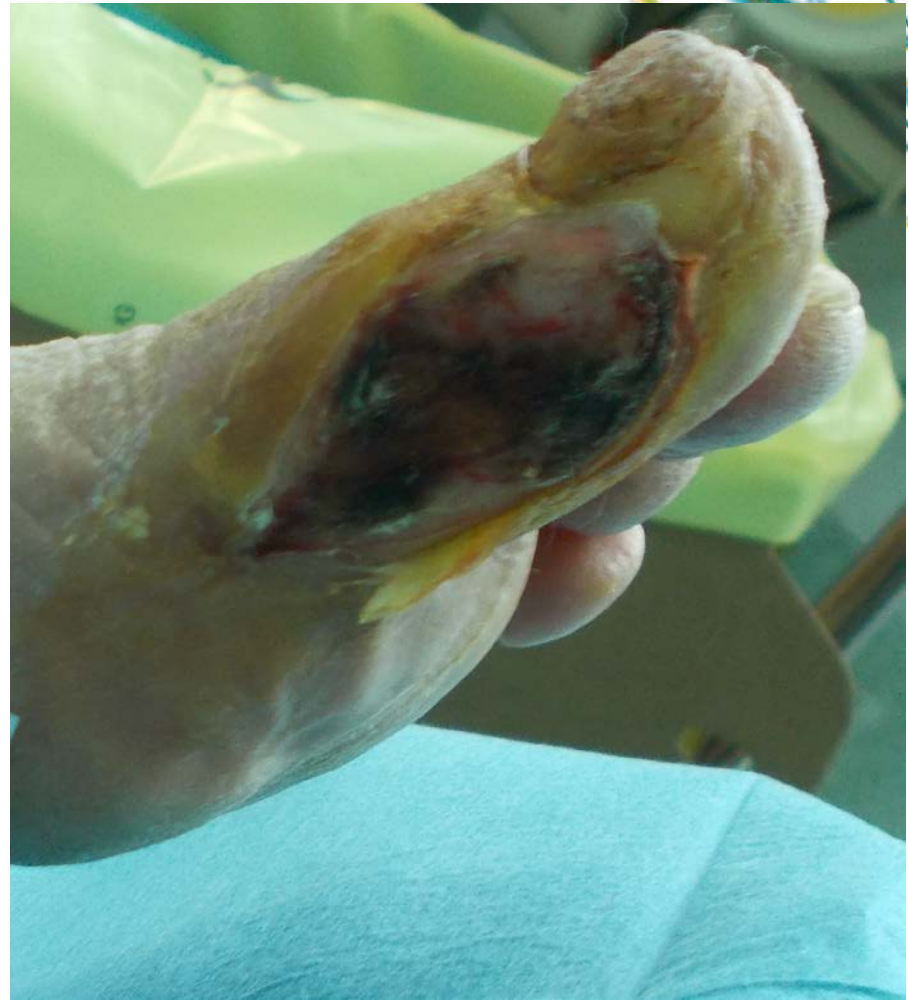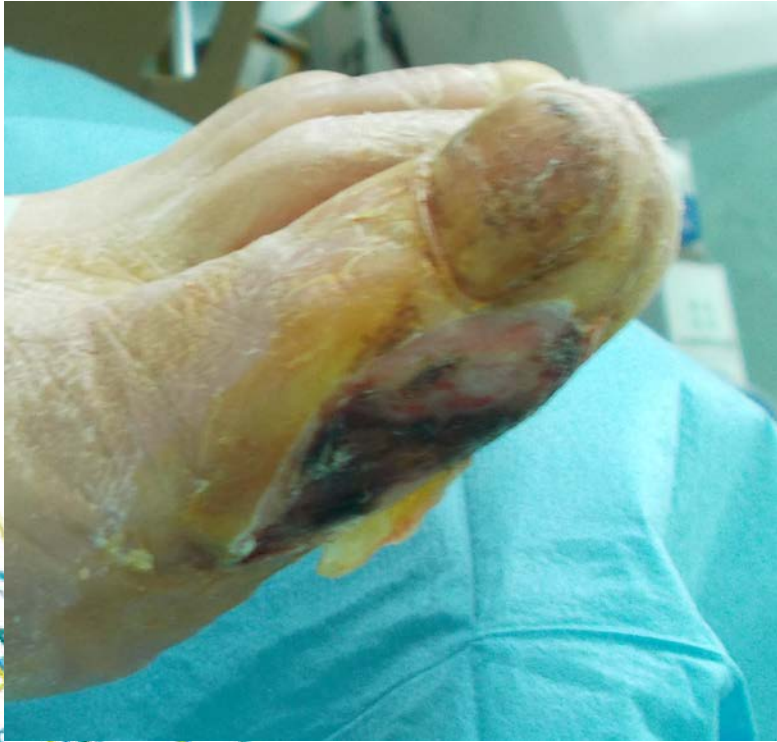# CASE 3

Male, 69 y-o, type 2 diabetes, hypertension, dyslipidemia.

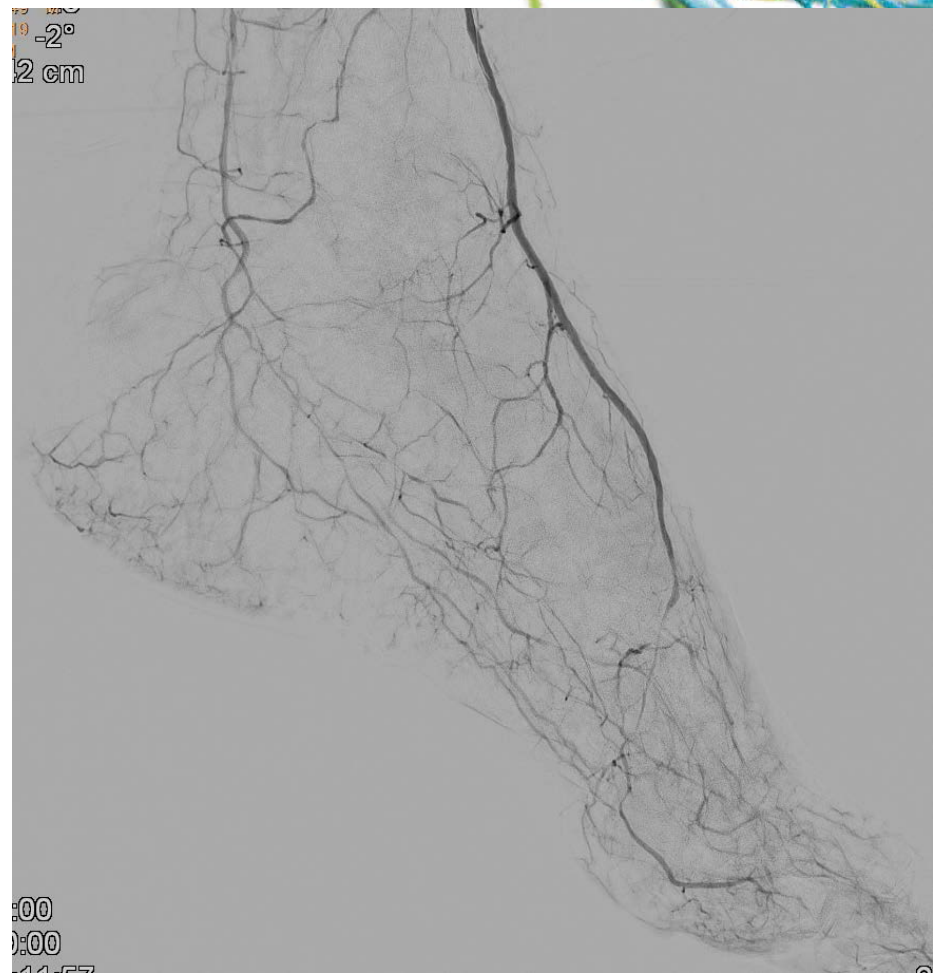
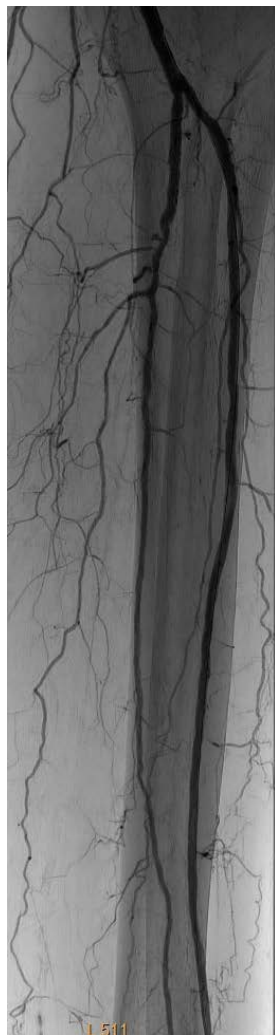
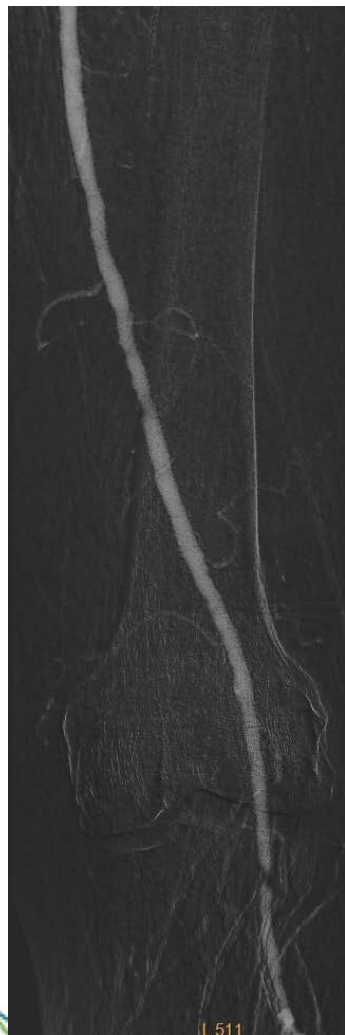
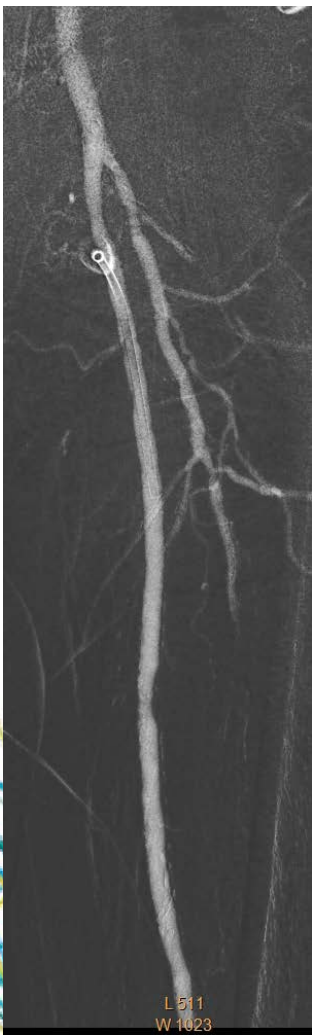Left CLI. No healing ulcer in the first toe.

Previous EVT (stenting in the TPT and PTA of ATA) one month ago.

# CASE 3







# CASE 3

## Strategy:

Antegrade 6F access. Antegrade recanalization of PT, if fails, Pedal-Plantar Loop.

0.018 - 0.014 Guide wire. Tokai support catheter.

Ultraverse balloon – Lutonix DCB