



MARCH  
21<sup>ST</sup> & 22<sup>ND</sup>  
2019  
PADUA  
ITALY

**CLIC**  
Critical Limb Ischemia Course

**LIVE CASES**  
**Thursday, March 21<sup>st</sup>**

# CASE 4

## Operators:

Dr. Palena – Dr. Herrero – Dr. Thomas

UNRESTRICTED  
SPONSORING

**Boston  
Scientific**

Advancing science for life™

# CASE 4


Male, 68 y-o, type 2 diabetes, hypertension, dyslipidemia, ischemic heart disease.

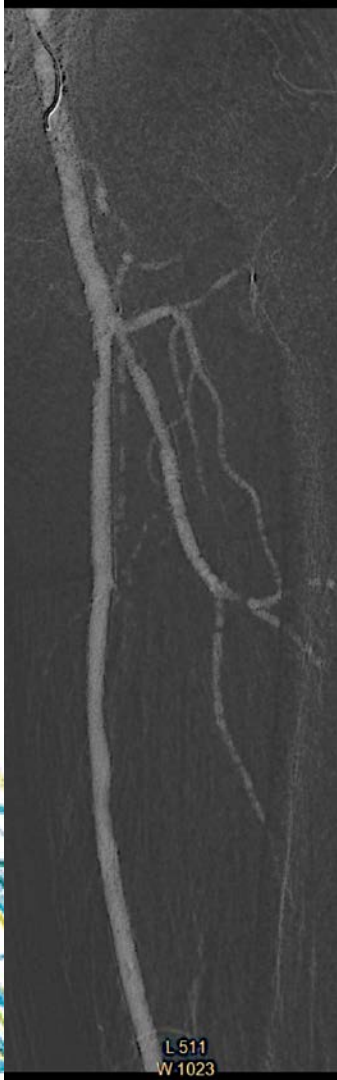Left CLI. Ulcer in the 1 toe (III-D TUC). TMA in the right leg.

First revascularization treatment.

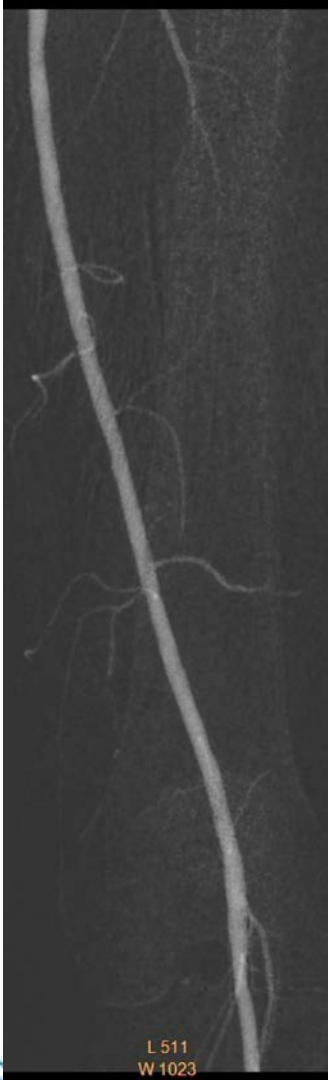CO2 Angio of the Left limb.

# CASE 4

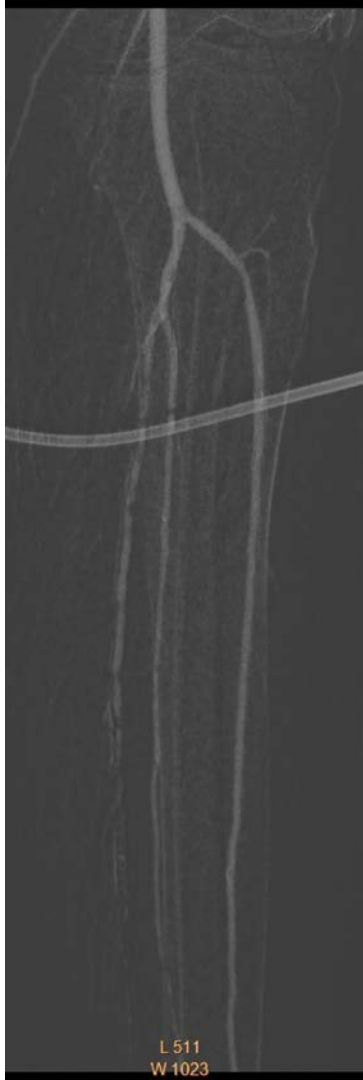




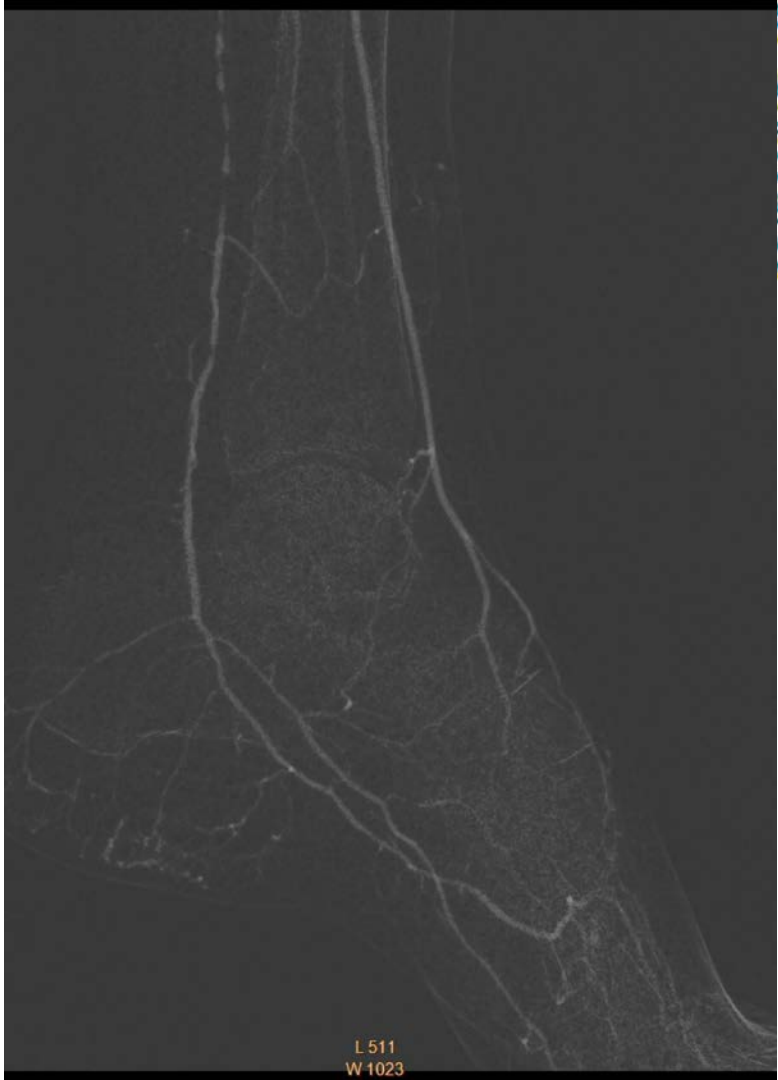
L 511  
W 1023



L 511  
W 1023



L 511  
W 1023



L 511  
W 1023

# CASE 4

## Strategy:

Antegrade 7F access. Antegrade recanalization of PT. Thruway 0.014 Guide wire.

Jetstream atherectomy POP/AT – Ranger DCB